

A Rare Case Report of Toxic Myocarditis and Acute Kidney Injury in a Case of Phencyclidine and Unknown Poisoning

Neha Luthra¹, Arunil Gupta², Akshat Kumar³, Pankaj Jhaldiyal⁴

Author's Affiliation:

¹PGY1 ²Attending Consultant ³PGY2
⁴HOD/Consultant, Department
of Emergency Medicine, Max
Superspeciality Hospital, Dehradun,
Uttarakhand 248001, India.

Corresponding Author:

Arunil Gupta, Attending Consultant,
Department of Emergency Medicine,
Max Superspeciality Hospital,
Dehradun, Uttarakhand 248001,
India.

E-mail: arunil.gupta1986@gmail.com

Received on 04.05.2018,

Accepted on 22.05.2018

Abstract

Phencyclidine (PCP, "angel dust") is a hallucinogenic well known for its ability to induce disorganized thought processes, including euphoria, omnipotence, superhuman strength, and amnesia and dysphoria. It is an illicit street drug which is used widely among youth in the United States. However in India, it is used by dacoits and thieves to sedate people and rob them in public transport. We report a case of a 25 yr old male who was brought to the ER from the local government hospital with altered sensorium. He had an alleged H/o of being found unconscious outside the local bus stop, possibly poisoned by dacoits. Early prompt resuscitation in the ER followed by early initiation of Sustained Low Efficiency Dialysis in view of Acute Kidney Injury and Early IABP Insertion led to the pt being successfully treated.

Keywords: Phencyclidine; Sustained Low Efficiency Dialysis; Acute Kidney Injury and IABP.

Introduction

Phencyclidine (PCP, "angel dust") is an infamous hallucinogenic sought for its ability to induce the illusion of euphoria, omnipotence, superhuman strength, and social and sexual prowess. The short form PCP comes from its organic name 1-(1-phenylcyclohexyl) piperidine, which indirectly suggests to its relatively simple production from the arylcyclohexylamine piperidine [1, 2].

More than 60 structurally similar yet more toxic forms than PCP, which were able to escape clinical detection, were common in the United States in 1980'S. Ketamine which was the only one authorized for medical use, was often stolen from veterinary clinics and hospitals due to its PCP-like effects [3].

Similarly to ketamine, PCP was earlier used as a preinduction agent in anesthesia and also as a tranquilizer for animals, hence was given the street names "horse tranquilizer," and "hog" [4,5]. It became popular because it provided anesthesia and analgesia without triggering cardiorespiratory

depression, but was withdrawn when patients experienced psychosis, agitation, and dysphoria post-operatively [6].

Although the cardiotoxic effects of PCP are very less documented but in this case the pt presented with cardiotoxicity and acute kidney injury along with acutely depressed mental status.

Case Report

A 25 male was brought to the ER with alleged history of being found in an unconscious state near the local bus terminal from where he was taken to the district hospital where after doing intubation and gastric lavage he was brought to MSSHD ER for further management.

Phase in ER

Vitals on arrival were Spo 2-86% on ambu bag, Pulse-150/min, BP-Not recordable and CBG-18mg/dl. The initial rhythm on the E.C.G was

broad complex QRS probable sine wave pattern. (Fig 1). In the ER Pt went into cardiac arrest 3 times with the rhythm being Polymorphic VT. (Figure 2).

Patient was actively resuscitated according to ACLS Protocol, Initial ABG showed high anion gap metabolic acidosis along with hypokalemia and high lactate levels. Pt was oligouric which gave a high suspicion of Acute Kidney Injury along with the ABG reports. Cardiology consult in the ER was done in view of repeated dysrhythmia revealed Global Hypokinesia with EF of 30-35%. Chest X ray showed early features of aspiration pneumonia. Pt was managed with high end Vasopressors, Dextrose infusion, Bicarbonate infusion, IV fluids and with amiodarone infusion for dysrhythmias. All the Blood investigations were send which revealed high TLC's, deranged Kidney Functions and deranged Liver Function Test. Pt was shifted to critical care unit for early dialysis and IABP insertion as advised by nephrology and cardiology.

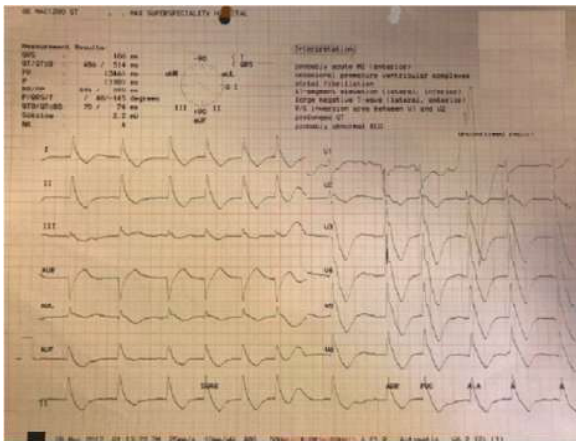


Fig. 1: Initial E.C.G. in the Emergency Department

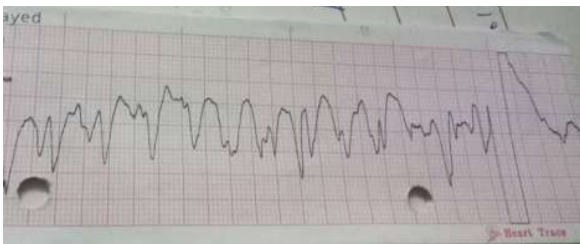


Fig. 2: Rhythm Strip Showing Polymorphic VT

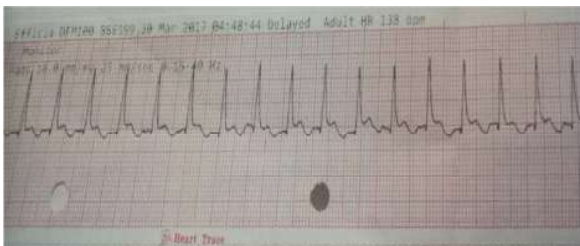


Fig. 3: Rhythm Strip Showing SVT with T-wave Inversion

Urine Drug Assay Panel			
Parameter Name	Result	Unit	Reference Range
Amphetamines (AMP)	Negative		
benzodiazepine Screen, Random Urine	Negative.		
BZD)			
cannabinoids, Random Urine (THC)	Negative.		
cocaine (COC)	Negative.		
opiates/Morphine Screen, Urine	Negative.		
(OR)			
barbiturates (BAR)	Negative.		
phencyclidine (PCP)	Positive		

Fig. 4: Urine for Toxicology Report showing Phencyclidine Positive

Phase in Critical Care

Taking in account the above findings and haemodynamic instability Sustained Low Efficiency Dialysis was started which continued for 18 hrs with UF of 1785 ml after which IABP was inserted. He was continued on Ventilatory and vasopressor support. Rhythm Showed SVT with T inversion, (Fig. 3.) His O₂ requirements decreased gradually. Pt's condition gradually improved and IABP was removed on the third day.

He was started on broad spectrum antibiotics after he developed episodes of fever and tracheal secretions showed bacterial growth. His blood and urine cultures were sterile. Pt's condition gradually improved with decreasing requirements for ventilator and vasopressor support. He was extubated on the 6th day and put on 60% ventury with 15L of O₂ and gradually this requirement also decreased and he started maintaining saturation on room air. Gradually his AKI/LFT's improved and EF also became better -45%. Urine for TOXICOLOGY revealed Phencyclidine (Fig. 4). With aggressive physiotherapy and mobilization pt felt a lot better and was ultimately discharged in stable condition on the 12th Day.

Discussion

Phencyclidine (PCP) is a compound derived from piperidine by chemical synthesis earlier used as an anesthetic and later on for drug abuse. There is little or no published data regarding the clinical presentation of PCP.

Over 50% of adult patients present with the classic toxidrome of PCP intoxication: violent behavior, nystagmus, tachycardia, hypertension, anesthesia, and analgesia.

PCP, also known as 1-(1-phenylcyclohexyl)-piperidine), is classified as a dissociative anesthetic. PCP acts mainly in the CNS, producing both stimulation and depression. Its sympathomimetic

effects are thought to be due to weak reuptake inhibition of norepinephrine and dopamine. PCP also exerts some cholinergic and anticholinergic effects and has some other actions at nicotinic and opioid receptors [1,2].

The dissociative properties of PCP are believed to be due to its actions as a glutamate antagonist at the N-methyl-D-aspartate (NMDA) receptors. NMDA antagonists have been known to produce behavioral effects similar to those observed in schizophrenia, and they are used to induce an animal model of schizophrenia for research. PCP also affects the actions of dopamine, which may cause the psychomotor effects seen with PCP [3,4].

Clinical effects occur within minutes and usually last several hours. These symptoms may last up to 48 hours in the event of significant overdose. However, even more prolonged effects may be seen in chronic users either from enterohepatic recirculation or from delayed release of PCP from lipid stores. Because PCP is fat soluble, it accumulates in adipose tissue and the brain. Recurrent and fluctuating symptoms occur as PCP is remobilized from lipid stores, which can occur days, weeks, or months after the initial use [2]. The half-life of PCP is estimated at 17.4 hours; however, half-lives of 1-4 days have been reported [3] PCP is primarily metabolized in the liver.

There is evidence of PCP directly irritating the heart by inducing arrhythmias and vasospasm. In addition, it may increase muscle tone, and patients may exhibit hyperreflexia, and myoclonic, dystonic or choreoathetoid movements such as opisthotonos and torticollis [9]. Complications of this hypertonic muscle activity include hyperthermia and rhabdomyolysis [9,14].

PCP intoxication may cause respiratory depression but not to the extent of intubation; however pt may experience episodes of both apnoea and tachypnoea [9,12]. Furthermore, hyperactive pharyngeal and laryngeal reflexes, and sympathomimetic effects create bronchorrhoea, which exacerbate the risk of airway obstruction in an already obtunded patient [9,12].

Rotatory nystagmus, ataxia, hyperthermia, and seizures at these doses has been Noted.

Conclusion

In conclusion, phencyclidine is a one of its kind drug that produces central nervous system depression and peripheral and central nervous system stimulation. Hallmark clinical findings of

PCP intoxication are nystagmus, hypertension and a mental status, which is often described as dissociative anesthesia. In higher doses patients become unconscious and can succumb to pulmonary aspiration and cardiovascular collapse [4,5,6].

In this case, it was shown that how early aggressive resuscitation in the ER followed by timely initiation of dialysis and IABP helped in this Patient's outcome. Although it should also be noted that the cardiac effects of PCP's are not so well documented but phencyclidine was detected in Urine on Tox Screen and also that the possibility of any other toxic compound which was not detected in the pt's urine cannot be ruled out.

References

1. NIDA PCP (Phencyclidine). NIDA Info Facts, <http://www.drugabuse.gov/PDF/Infofacts/PCP06.pdf>. Washington (DC), USA: U.S. Department of Health and Human Services 2006. pp.1-3.
2. Marquis KL, Moreton JE. Animal models of intravenous phencyclidinoid self-administration. *Pharmacol Biochem Behav.* 1987;27:385-89.
3. Wright RO, Woolf AD. Phencyclidine. In: Haddad LM, editor. *Clinical Management of Poisoning and Drug Overdose*. Philadelphia, USA: W.B. Saunders; 1998. pp.552-559.
4. Lundberg GD, Gupta RC, Montgomery SH. Phencyclidine: patterns seen in street drug analysis. *Clin Toxicol.* 1976;9:503-11.
5. Weaver MF, Jarvis MA, Schnoll SH. Role of the primary care physician in problems of substance abuse. *Arch Intern Med.* 1999;159:913-24.
6. Olmedo R. Phencyclidine and Ketamine. In: Goldfrank LR, editor. *Goldfrank's Toxicologic Emergencies*. New York, USA: McGraw-Hill; 2002. pp.1034-45.
7. O'Shea B. Phencyclidine, ketamine, and khat phencyclidine (PCP, DOA, 'angel dust', 'crystal', 'hog') *Ir Med J.* 2000;93:185.
8. Poklis A, Maginn D, Barr JL. Drug findings in 'Driving Under the Influence of Drugs' cases: a problem of illicit drug use. *Drug Alcohol Depend.* 1987;20:57-62.
9. McCarron MM, Schulze BW, Thompson GA, Conder MC, Goetz WA. Acute phencyclidine intoxication: incidence of clinical findings in 1,000 cases. *Ann Emerg Med.* 1981;10:237-42.
10. Welch MJ, Correa GA. PCP intoxication in young children and infants. *Clin Pediatr (Phila)* 1980;19:510-14.
11. Cook CE, Brine DR, Jeffcoat AR, et al. Phencyclidine disposition after intravenous and oral doses. *Clin Pharmacol Ther.* 1982;31:625-34.

12. Cook CE, Perez-Reyes M, Jeffcoat AR, Brine DR. Phencyclidine disposition in humans after small doses of radiolabeled drug. *Fed Proc.* 1983;42:2566-69.
 13. Schwartz RH, Einhorn A. PCP intoxication in seven young children. *Pediatr Emerg Care.* 1986;2:238-241.
 14. McCarron MM, Schulze BW, Thompson GA, Conder MC, Goetz WA. Acute phencyclidine intoxication: clinical patterns, complications, and treatment. *Ann Emerg Med.* 1981;10:290-97.
 15. Walberg CB, McCarron MM, Schulze BN. Quantitation of phencyclidine in serum by enzyme immunoassay: results in 405 patients. *J Anal Toxicol.* 1983;7:106-10.
-